

**Case Report – Endourology**

First Successful Endoscopic Removal of a Pen from the Male Urinary Bladder (Erkek Mesanesinden İlk Başarılı Endoskopik Kalem Çıkarma Operasyonu)

Somanatha Prathyangira Sharma, Javangula Venkata Surya Prakash, Vetrivel Natarajan

Department of Urology, Government Stanley Medical College, The Tamil Nadu Dr. M.G.R. Medical University, Chennai, India


Cite as: Sharma SP, Prakash JVS, Natarajan V. First successful endoscopic removal of a pen from the male urinary bladder. *Grand J Urol* 2024, DOI: 10.5505/GJU.2024.39200 [Epub Ahead of Print]

Submission date: 18 January 2024 **Acceptance date:** 28 February 2024 **Online first:** 04 March 2024

Publication date:

Corresponding Author: Somanatha Prathyangira Sharma / The Tamil Nadu Dr. M.G.R. Medical University, Government Stanley Medical College, Department of Urology, Chennai, India / spideysoms@gmail.com / ORCID ID: 0000-0002-4876-0389

This is a PDF file of an unedited manuscript that has been accepted for publication. As a service to our authors, we are providing this early version of the manuscript. The version will undergo copyediting, typesetting and review before it is published in its final form. Please note that during the production process errors may be discovered which could affect the content, and all legal disclaimers that apply to the journal pertain.

© Copyright 2024 by GJU.  First successful endoscopic removal of a pen from the male urinary bladder by Somanatha Prathyangira Sharma is licensed under a [Creative Commons Attribution-NonCommercial 4.0 International License](https://creativecommons.org/licenses/by-nc/4.0/) which permits unrestricted non-commercial re-use, distribution, and reproduction in any medium, provided the original work is properly cited.

Abstract

Self-inflicted foreign bodies in the urinary bladder are very rarely reported. Insertion of a wide variety of objects into bladder due to autoerotic stimulation, psychiatric disturbances, and senility etc. have been reported in the medical literature. This case report discusses an exceptional incident where a young male patient self-inserted a ball-point pen into his urinary bladder via the urethra. Notably, the pen negotiated the curvatures of the urethra without causing significant lower urinary tract injury. The report underscores the challenges and successful endoscopic removal of the pen, marking the first documented instance of such an extraction in a male patient.

Keywords: pen, foreign body, bladder, endoscopic extraction

Özet

İdrar kesesine kendi kendine yabancı cisim sokulması çok nadir olarak bildirilmiştir. Otoerotik stimülasyon, psikiyatrik rahatsızlıklar ve yaşlılık gibi nedenlerle mesaneye çok çeşitli cisimlerin sokulması tıbbi literatürde bildirilmiştir. Bu vaka raporunda, genç bir erkek hastanın üretra yoluyla idrar kesesine tükenmez kalem kendi kendine soktuğu istisnai bir olay tartışılmaktadır. Özellikle, kalem üretranın eğriliklerini önemli bir alt üriner sistem yaralanmasına neden olmadan aşmıştır. Rapor, erkek bir hastada bu tür bir çıkarma işleminin belgelenmiş ilk örneğini işaret ederek, kalemin endoskopik olarak çıkarılmasının zorluklarını ve başarısını vurgulamaktadır.

Anahtar kelimeler: kalem, yabancı cisim, mesane, endoskopik ekstraksiyon

Introduction

The presence of self-inflicted foreign bodies in the urinary bladder is an uncommon phenomenon, with objects typically small in size and associated with factors like sexual gratification, psychiatric disorders, or advanced age [1]. In literature, there have been reports of long foreign bodies such as pens, pencils, telephone cable, beading awl and thermometer that have been found in the bladder [2,3,4,5,6,7]. This case presents the unique instance of a self-inserted ball-point pen in a male patient's bladder, successfully removed through endoscopic methods using a nephroscope cystoscopy.

Case

A 34-year-old migrant laborer experienced dysuria, terminal hematuria, and suprapubic pain following self-insertion of a ball-point pen into the urinary bladder during masturbation. Radiological examinations confirmed the intravesical location of the pen [Figure 1,2]. Under regional anesthesia, we performed cystoscopy with a 20 F 30-degree telescope which revealed intact anterior and posterior urethra, with minor mucosal injuries in the posterior urethra. The freely moving pen in the bladder and its impingement on the bladder wall were noted [Figure 3]. Initial cystoscopic extraction attempts to grab its freely dangling distal end with a conventional cold-cup grasper failed due to the wide diameter of the pen. A three-prong grasper was delivered through the work channel of a 22 F rigid nephroscope introduced through urethra and the pen was extracted successfully highlighting the need for adaptive techniques in endoscopic procedures [Figure 4,5]. Despite the challenges such as the sharp tip, wide diameter and slippery surface of the pen, the three-prong grasper enabled successful extraction without significant mucosal injuries. The procedure was completed in less than 40 minutes, emphasizing the importance of precise maneuvering in overcoming such challenges.

Discussion

The insertion of foreign bodies into the urinary bladder, termed as "self-inflicted urethral foreign body insertion," is a rare but documented phenomenon. While successful extraction of foreign bodies from the female urinary bladder has been documented [6], extracting them from the male urinary bladder presents distinct anatomical and technical challenges [4,5]. Previous reports have described cases of bladder perforation, migration of foreign bodies into the abdominal cavity, and the need for open surgical interventions in these patients [7-10]. Therefore, the successful endoscopic extraction presented in this case adds valuable insights to the existing body of literature and reinforces the feasibility of minimally invasive approaches in managing such cases. The successful transurethral removal of a pen from inside the male urinary bladder using endoscopic methods marks a significant milestone in urological practice. This case underscores the importance of employing adaptive techniques and specialized equipment, such as rigid nephroscopes and three-prong graspers, in addressing unique challenges posed by long and rigid foreign bodies. The ability to negotiate through the urethral curvatures and extract the pen without causing significant mucosal injuries highlights the expertise and skill required in endourological procedures. Nevertheless, urologists should be prepared to switch to open surgical procedures if endoscopic extraction is unsuccessful, in

the absence of appropriate endoscopic equipment or they have insufficient surgical expertise in endoscopic techniques [11,12].

Conclusion

In conclusion, the successful endoscopic extraction of a ball-point pen from inside the male urinary bladder highlights the efficacy of minimally invasive approaches in managing complex cases of self-inflicted foreign bodies. This case demonstrates that long foreign objects can be effectively removed endoscopically, provided that appropriate endoscopic instruments, and equipment are readily available.

Ethics Committee Approval: N / A.

Informed Consent: An informed consent was obtained from the patient.

Publication: The results of the study were not published in full or in part in form of abstracts.

Peer-review: Externally peer-reviewed.

Authorship Contributions: Any contribution was not made by any individual not listed as an author. Concept – S.P.S., J.V.S P., V. N.; Design – S.P.S., J.V.S P., V. N.; Supervision – S.P.S., J.V.S P., V. N.; Resources – S.P.S., J.V.S P., V. N.; Materials – S.P.S., J.V.S P., V. N.; Data Collection and/or Processing – S.P.S., J.V.S P., V. N.; Analysis and/or Interpretation – S.P.S., J.V.S P., V. N.; Literature Search – S.P.S., J.V.S P., V. N.; Writing Manuscript – S.P.S., J.V.S P., V. N.; Critical Review – S.P.S., J.V.S P., V. N.

Conflict of Interest: The author declares that there was no conflict of interest.

Financial Disclosure: The author declares that this study received no financial support.

References

- [1] Rahman NU, Elliott SP, McAninch JW. Self-inflicted male urethral foreign body insertion: endoscopic management and complications. BJU Int. 2004;94(7):1051-3. <https://doi.org/10.1111/j.1464-410X.2004.05103.x>
- [2] Bonatsos V, Batura D. PENs in the PENis: a case report and brief review of the literature. Afr J Urol. 2021;27:77. <https://doi.org/10.1186/s12301-021-00180-8>
- [3] Trehan RK, Haroon A, Memon S, Turner D. Successful removal of a telephone cable, a foreign body through the urethra into the bladder: a case report. J Med Case Rep. 2007;1:153. <https://doi.org/10.1186/1752-1947-1-153>
- [4] Agarwal M, Aggarwal A, Pandey S, Kumar M. Knotted electric wire in urinary bladder: Can such complex foreign body be retrieved endoscopically! BMJ Case Rep. 2018;2018:bcr2018225353. <https://doi.org/10.1136/bcr-2018-225353>

[5] Balci U, Horsanali MO, Kartalmis M, Girgin C, Dincel C. An unusual foreign body in the urinary bladder: beading awl. Urol Res Pract. 2011;37(3):275-7. <https://urologyresearchandpractice.org/>

[6] Raheem AA, Hafez K, Sherbini A, Zoair A, Eissa A. Cystoscopic extraction of a whole pen from the bladder: A case report and review of bladder foreign bodies' treatment options. World J Nephrol Urol. 2014;3(1):54-7. <https://doi.org/10.14740/wjnu150w>

[7] Bantis A, Sountoulides P, Kalaitzis C, Giannakopoulos S, Agelonidou E, Foutzitzi S, et al. Perforation of the urinary bladder caused by transurethral insertion of a pencil for the purpose of masturbation in a 29-year-old female. Case Rep Med. 2010;2010:460385. <https://doi.org/10.1155/2010/460385>

[8] Nishiyama K, Shimada T, Yagi S, Kawahara M, Nakagawa M. Endoscopic removal of intravesical thermometer using a rigid nephroscope and forceps. Int J Urol. 2002;9(12):717-8. <https://doi.org/10.1046/j.1442-2042.2002.00545.x>

[9] Moslemi MK, Sorani M. Self-inflicted male bladder foreign body: its endoscopic removal using a rigid cystoscope and a suprapubic forceps. Case Rep Urol. 2013;2013:729013. <https://doi.org/10.1155/2013/729013>

[10] Aljarbou, A, Abdo AJ, Almosa MA, Hariri A. Extraction of foreign body from the urinary bladder using nephroscope: A case report of endoscopy treatment. Urol Ann. 2023;15(1):95-7. https://doi.org/10.4103/ua.ua_109_22

[11] Rafique M. Intravesical foreign bodies: review and current management strategies. Urol J. 2008;5(4):223-31. <https://pubmed.ncbi.nlm.nih.gov/19101894/>

[12] Bansal A, Yadav P, Kumar M, Sankhwar S, Purkait B, Jhanwar A, et al. Foreign Bodies in the Urinary Bladder and Their Management: A Single-Centre Experience From North India. Int Neurourol J. 2016;20(3):260-9. <https://doi.org/10.5213/inj.1632524.262>

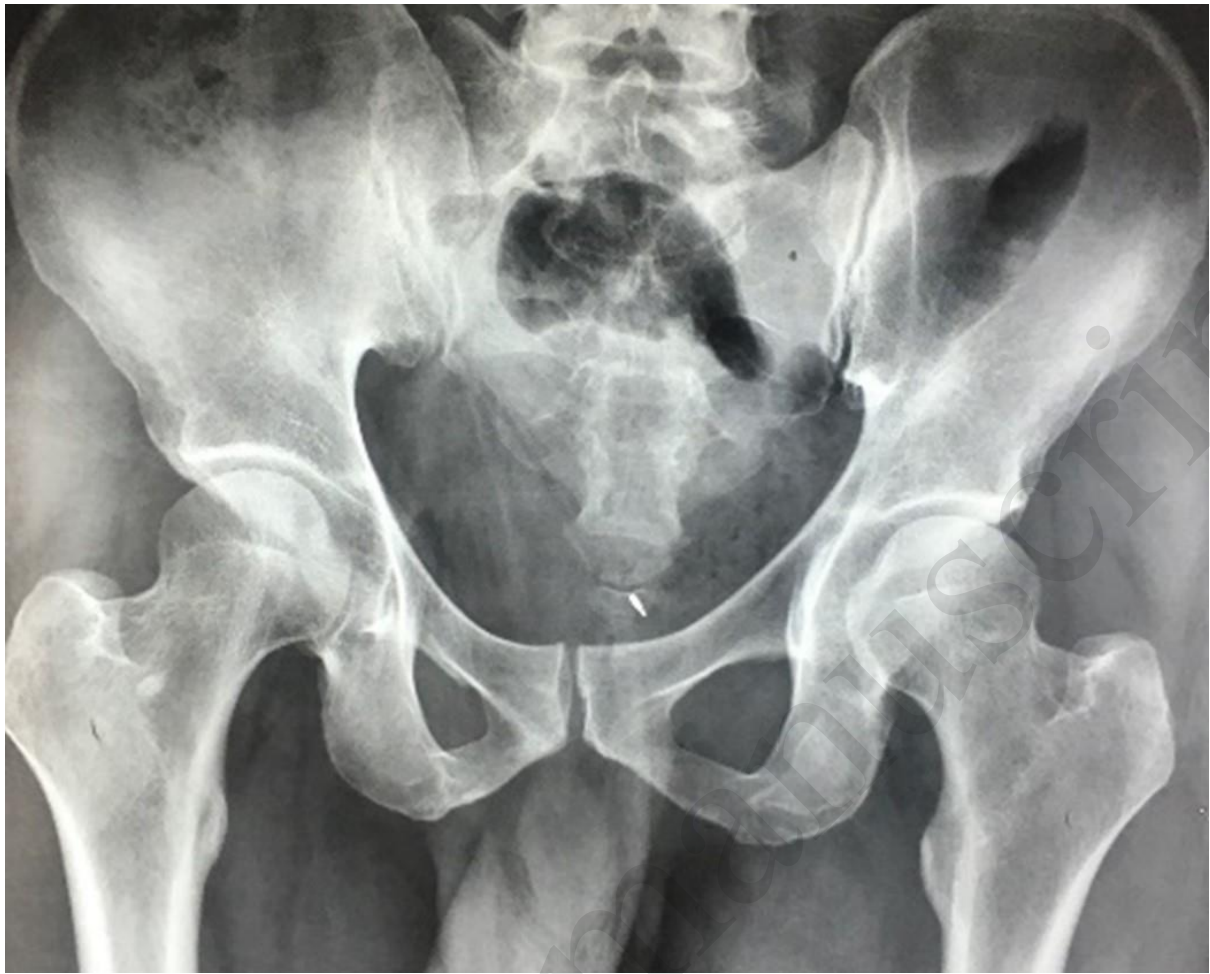

Figure 1. X-ray of the pelvis depicting the metal portion of a linear foreign body within the bladder region

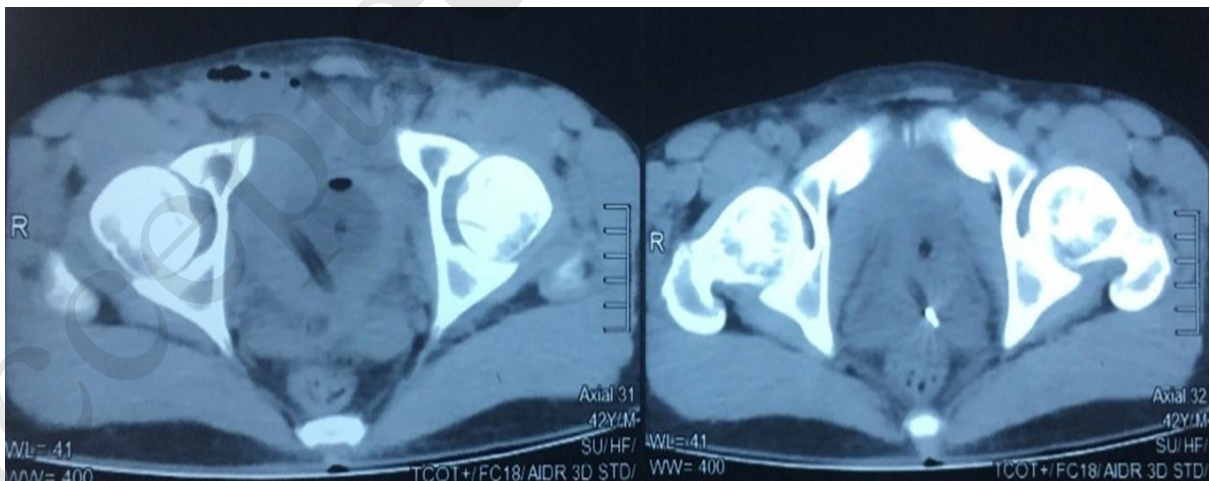


Figure 2. CT-KUB confirming the presence of the foreign body in the bladder without any signs of bladder perforation

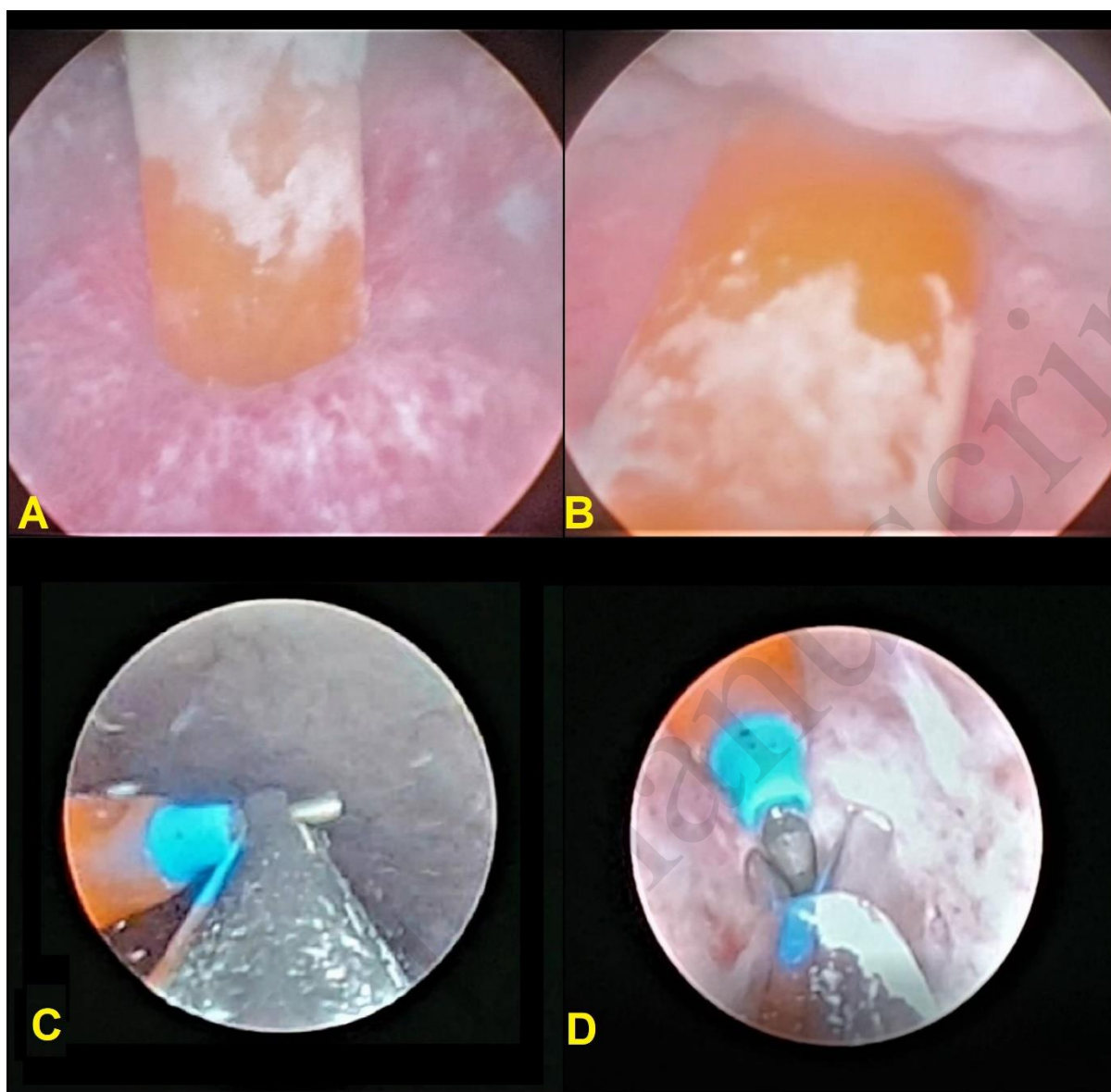


Figure 3. Cystoscopic observation displaying both ends of the foreign body within the bladder (A, B); Successful extraction of the pen through endoscopy using a nephroscope and tri-prongs grasper (C, D)



Figure 4. Armamentarium used for the extraction; 22 F rigid nephroscope and tri-prongs grasper, alongside the successfully removed foreign body

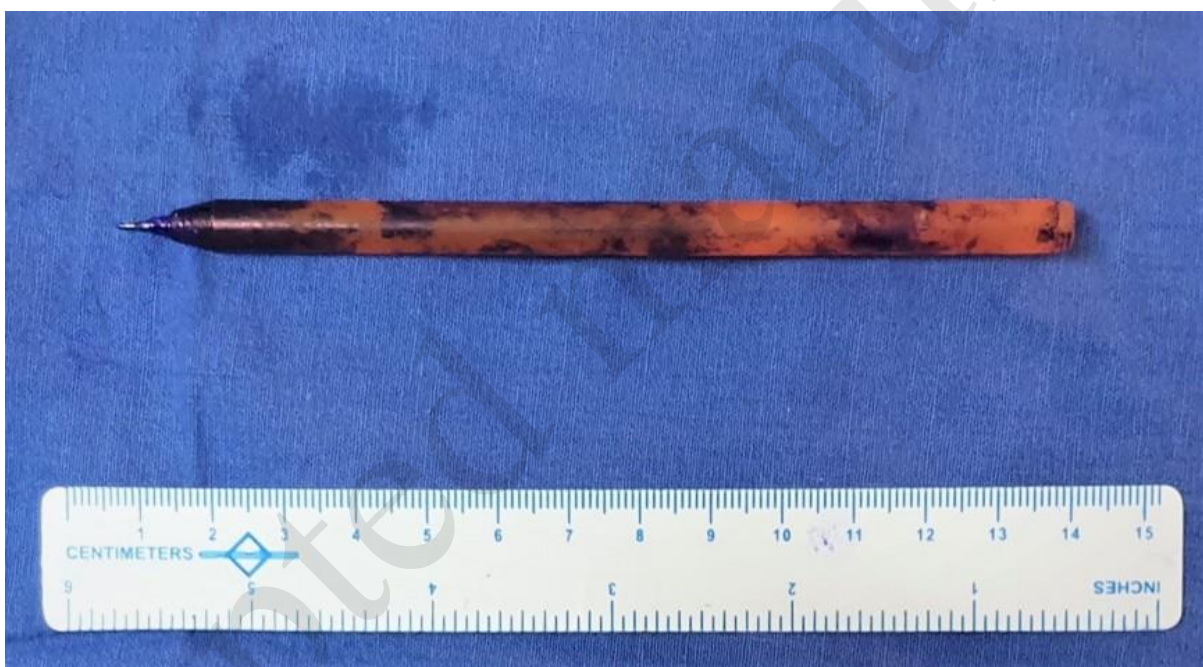

Figure 5. Extracted pen from the bladder measuring 13 cm in length