

A Rare Cause of Acute Urinary Retention in a Young Man: Zinner Syndrome

Genç Bir Erkekde Akut Üriner Retansiyonun Nadir Bir Nedeni: Zinner Sendromu

Murat Yavuz Koparal , Ugur Aydin , Burak Elmas , Ender Cem Bulut , Serhat Cetin , Fazli Polat , Ali Atan 

Department of Urology, Gazi University Faculty of Medicine Hospital, Ankara, Turkey

Cite as: Koparal MY, Aydin U, Elmas B, Bulut EC, Cetin S, Polat F, Atan A. A rare cause of acute urinary retention in a young man: Zinner syndrome. Grand J Urol 2022;2(3):122-5.

Submission date: 14 May 2022

Acceptance date: 24 August 2022

Online First: 31 August 2022

Publication date: 20 September 2022

Corresponding Author: Murat Yavuz Koparal / Gazi University Faculty of Medicine Hospital, Department of Urology, Ankara, Turkey / drmykoparal@gmail.com / ORCID ID: 0000-0002-8347-5727

Abstract

Zinner syndrome is a rarely seen congenital anomaly characterized with developmental defects of mesonephric (Wolffian) duct including obstruction of the ejaculatory duct, an ipsilateral seminal vesicle cyst, and an ipsilateral renal agenesis. Patients may present with genitourinary system complaints, or they may be completely asymptomatic and detected incidentally. Minimally invasive cyst aspiration and surgical treatment are mainly aimed for symptomatic relief. In this article, a rare case of Zinner Syndrome presenting with signs of urinary retention is presented.

Keywords: Zinner, seminal vesicle cyst, urinary retention, renal agenesis

Öz

Zinner sendromu, ejakülatör kanal obstrüksiyonu, ipsilateral seminal vezikül kisti ve ipsilateral renal agenezi gibi mezonefrik (Wolffian) kanal gelişim bozukluğu ile karakterize nadir görülen bir konjenital anomalidir. Hastalar genitoüriner sistem şikayetleri ile başvurabileceği gibi tamamen asemptomatik olup tesadüfen saptanabilir. Minimal invaziv kist aspirasyonu ve cerrahi tedavi esas olarak semptomatik rahatlama amaçlar. Bu makalede nadir görülen ve üriner retansiyon bulgusu ile başvuran bir Zinner Sendromu vakası sunulmuştur.

Anahtar kelimeler: Zinner, seminal vezikül kist, üriner retansiyon, renal agenezi

ORCID ID: U. Aydin 0000-0001-8024-6438
B. Elmas 0000-0003-0131-0740

E.C. Bulut 0000-0002-5002-5471
S. Cetin 0000-0001-5450-5168

F. Polat 0000-0002-1219-5082
A. Atan 0000-0002-7114-068X

Introduction

Zinner syndrome is a rarely seen congenital anomaly characterized by developmental defects of mesonephric (Wolffian) duct. The classic triad includes ejaculatory duct obstruction, an ipsilateral seminal vesicle cyst, and an ipsilateral renal agenesis. It was first described by A. Zinner in 1914 [1]. Bladder neck, half of the trigone, urethra, vas deferens, seminal vesicles, and epididymis in men develop from the distal mesonephric duct under the influence of testosterone and anti-Müllerian hormone. During embryogenesis, developmental disorders of the distal mesonephric duct affect the formation of the ipsilateral kidney, ureter, vas deferens, and seminal vesicles. The ejaculatory duct obstruction results in cystic dilatation of seminal vesicles because of the accumulation, and retention of seminal fluid. Patients may present with genitourinary system complaints, or they may be completely asymptomatic and detected incidentally. In this paper, we report a case of a 32-year-old male patient who presented with acute urinary retention, and diagnosed as Zinner syndrome based on radiological examinations.

Case

A 32-year-old male patient was admitted to the emergency department complaining of an inability to urinate for hours. He had been complaining of frequent episodes of difficult micturition for three weeks. He had no known urological or systemic diseases. His vital signs were within normal limits at the time of admission. Suprapubic tenderness and distension due to a distended urinary bladder were revealed upon physical examination. No abnormality was detected during the physical examination of the external genitalia. The results of urinalysis, hematological and biochemical blood tests were within normal limits. Following the insertion of a 16-F urethral catheter, he was referred to the urology department for further examination.

Abdominopelvic ultrasound (US) was performed and a hypertrophic left kidney (Grade 1) with increased echogenicity was seen and the right kidney could not be visualized. A lobulated multiloculated cystic lesion of approximately 7.5x6.0 cm in size in the posterior region of the bladder compressing the prostate and the bladder was observed. Then, a magnetic resonance imaging (MRI) of the lower abdomen was performed. On MRI, cystic enlargement reaching 3.5 cm in diameter at the widest point of the left seminal vesicle and compressed bladder was detected. The left seminal vesicle was not separate from this cystic lesion (**Figure 1**). Fluid-fluid levels were noted in the dilated left vas deferens possibly secondary to dense, proteinous content. The left ureter showed indentation with ureterocele which apparently terminated proximally at the level of the left sacroiliac joint. The right ureter, right seminal vesicle, and prostate were morphologically normal.

The radiological findings of the left seminal vesicle cyst with ipsilateral renal agenesis, tubular enlargement of ipsilateral vas deferens, and left ureterocele with blind-ending proximal ureter led to the establishment of the diagnosis of Zinner syndrome, which is a mesonephric duct anomaly. Since acute urinary retention

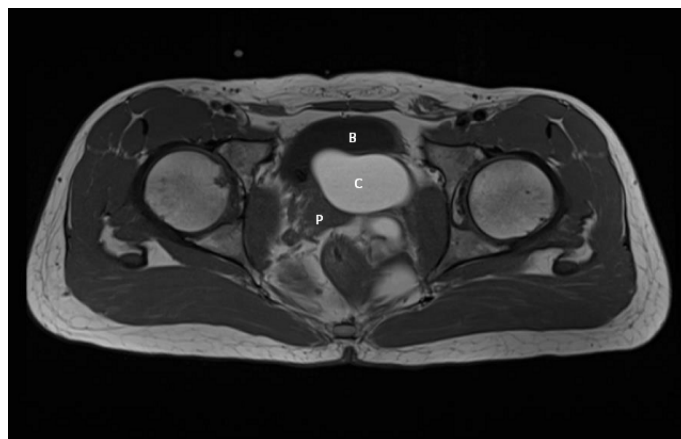


Figure 1. Axial T1-weighted images of MRI. The cystic lesion (C) at the level of the left seminal vesicle compresses on the bladder (B) from the posterior and on the prostate (P) from the lateral

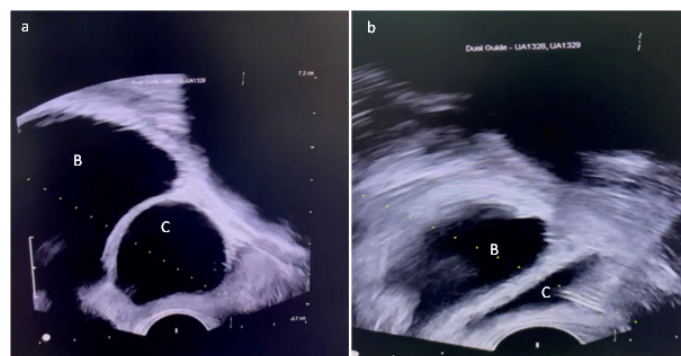


Figure 2. Sagittal view of transrectal ultrasound before (a) and after (b) transrectal needle aspiration of cystic lesion (C) on the posterior of the bladder (B). It was observed that the cystic lesion shrunk and disappeared after aspiration



Figure 3. Dark-colored aspirated liquid of cystic lesion

developed, transrectal needle aspiration was performed under the guidance of transrectal US (**Figure 2a**). Cystic dilatation regressed completely after aspiration (**Figure 2b**) of a dark-colored liquid (**Figure 3**). The urethral catheter was removed at the 24th hour after percutaneous aspiration. The patient was discharged after he urinated without difficulty. A control visit was scheduled for approximately one month after the procedure.

Discussion

Current hypotheses regarding the pathogenesis of Zinner syndrome are related to disruptions in the development of the mesonephric duct or Wolffian duct. In normal embryological development, the mesonephric duct performs some basic renal functions. Also, the presence of testosterone in males stimulates the distal end of the mesonephric duct to differentiate into the epididymis, vas deferens, seminal vesicles, and bladder trigone. Dysfunction of signaling pathways during development of the distal mesonephric duct may result in agenesis or dysplasia of the ureteral bud (and subsequently the ipsilateral kidney) or genital adnexal structures (such as the ipsilateral seminal vesicle) [2].

In this case report, we are presenting a case of Zinner syndrome that referred to us with acute urinary retention and the diagnosis was established based on MRI findings. Then, we performed transrectal aspiration of the cyst under US guidance. We performed radiological tests during control visits to see if there was any recurrence of cysts. Recurrence of cysts was not observed during control visits. The patient did not have urinary retention or difficulty urinating again. Zinner syndrome is mostly asymptomatic. Symptoms classically occur at the age of peak sexual and reproductive activity due to the accumulation of seminal fluid in the seminal vesicles. Most of the symptomatic cases present with lower urinary tract symptoms such as enlarged seminal vesicle cyst, dysuria, pollakiuria, painful ejaculation, perineal pain, and epididymitis. Although rare, patients may also present with infertility [3], hematospermia [4], scrotal pain [5], and difficult micturition [6]. Because this syndrome has broad-spectrum symptoms, the diagnosis of infertility may be delayed. In pediatric age, congenital seminal vesicle cysts may be asymptomatic and may be diagnosed incidentally during routine radiological imaging during postnatal US scanning for urinary tract anomalies or during neonatal US in patients with suspected prenatal renal malformation. Seminal vesicle cysts are present from birth but grow and become symptomatic in adolescence or adulthood [7].

Zinner syndrome is diagnosed radiologically using various imaging methods. The gold standard diagnostic imaging techniques include US or CT in the first stage and MRI imaging as a further examination [8]. Ureteral anomalies may present in different forms in Zinner syndrome. The ipsilateral ureter may be completely agenetic [2] or may present as a blind-ending ureterocele [9] or ureter opening into the seminal vesicle [10].

As a treatment modality incidentally asymptomatic or minimally symptomatic cases may be followed up. Treatment is mainly aimed at symptomatic relief. In a recently published systematic review of 214 cases, surgery was the most common treatment approach performed. Surgery can be performed as an open, robotic, or laparoscopic vesiculectomy. Seminal vesiculoscopy, transurethral unroofing of the cyst, and transurethral resection of the ejaculatory duct are other rarely applied surgical treatment options. Percutaneous drainage and transrectal aspiration are less invasive methods that can be applied as an alternative to surgery. In a study recurrence was reported in 8 out of 19 (47.4%) patients who had undergone transrectal cyst aspiration requiring surgical treatment [11].

Ethics Committee Approval: N / A.

Informed Consent: An informed consent was obtained from the patient.

Publication: The results of the study were not published in full or in part in form of abstracts.

Peer-review: Externally peer-reviewed.

Authorship Contributions: Any contribution was not made by any individual not listed as an author. Concept – M.Y.K., U.A.; Design – M.Y.K., U.A.; Supervision – M.Y.K., A.A.; Resources – B.E., E.C.B., S.C., F.P.; Materials – B.E., E.C.B., S.C., F.P.; Data Collection and/or Processing – B.E., E.C.B., S.C., F.P.; Analysis and/or Interpretation – M.Y.K., U.A. A.A.; Literature Search – B.E., E.C.B., S.C., F.P.; Writing Manuscript – M.Y.K., U.A.; Critical Review – M.Y.K., A.A.

Conflict of Interest: The authors declare that they have no conflict of interest.

Financial Disclosure: The authors declare that this study received no financial support.

References

- [1] Zinner A. Ein fall von intravesikaler Samenblasenzyste. *Wien Med Wochenschr* 1914;64:605-9.
- [2] Kwenda EP, Locke RA, Archer JS, Su L-M, Shenoy A, DeMarco RT, et al. Robot-assisted laparoscopic resection of the mesonephric duct remnant in a patient with Zinner syndrome. *J Endourol Case Rep* 2020;6:198-201. <https://doi.org/10.1089/cren.2020.0020>. eCollection 2020.
- [3] Cito G, Sforza S, Gemma L, Cocci A, Di Maida F, Dabizzi S, et al. Infertility case presentation in Zinner syndrome: Can a long-lasting seminal tract obstruction cause secretory testicular injury? *Andrologia* 2019;51:e13436. <https://doi.org/10.1111/and.13436>.
- [4] Canales-Casco N, Dominguez-Amillo A, Arrabal-Polo MA, Sanchez-Tamayo FJ, Arrabal-Martin M, Cozar-Olmo JM. Hematospermia as a Rare Form of Presentation of Zinner Syndrome. *Urology* 2017;99:e15-e6. <https://doi.org/10.1016/j.urology.2016.09.030>.
- [5] Florim S, Oliveira V, Rocha D. Zinner syndrome presenting with intermittent scrotal pain in a young man. *Radiol Case Rep* 2018;13:1224-7. <https://doi.org/10.1016/j.radcr.2018.08.012>.
- [6] Kori R, Bains L, Lal P, Gupta S. Zinner syndrome mimicking bladder outlet obstruction managed with aspiration. *Urol Ann* 2019;11:449-52. https://doi.org/10.4103/UA.UA_152_18.
- [7] Kao C-C, Wu C-J, Sun G-H, Yu D-S, Chen H-I, Chang S-Y, et al. Congenital seminal vesicle cyst associated with ipsilateral renal agenesis mimicking bladder outlet obstruction: a case report and review of the literature. *Kaohsiung J Med Sci* 2010;26:30-4. [https://doi.org/10.1016/S1607-551X\(10\)70005-X](https://doi.org/10.1016/S1607-551X(10)70005-X).
- [8] Yousaf A, Fazeel HM, Shah MH, Ghaffar F, Batool SS. Zinner Syndrome Unmasked by Workup for Renal Colic and Uncontrolled Hypertension. *Cureus* 2020;12: e8381. <https://doi.org/10.7759/cureus.8381>.

- [9] Maehana T, Fukuta F, Kobayashi K, Hirobe M, Tanaka T, Masumori N. Laparoscopic surgery for seminal vesicle cysts and ureterocele with urination disorder: a case report of Zinner syndrome. *J Endourol Case Rep* 2018;4:35-8. <https://doi.org/10.1089/cren.2018.0008>.
- [10] Cooper M, Wiegand L. An unusual variant of Zinner syndrome with ureteral ectopia from an atrophied supernumerary kidney. *Urol Case Rep* 2020;31:101160. <https://doi.org/10.1016/j.eucr.2020.101160>.
- [11] Liu T, Li X, Huang L, Li H, Cai K, Jiang J, et al. Zinner syndrome: an updated pooled analysis based on 214 cases from 1999 to 2020: systematic review. *Ann Palliat Med* 2021; 10:2271-82. <https://doi.org/10.21037/apm-20-1997>.